

Possible Protective Effects of Mirabegron on Experimentally Induced Non-alcoholic Steatohepatitis in Rats

Abstract:

Background: Non-alcoholic fatty liver disease (NAFLD) is the most common chronic liver disease worldwide. Mirabegron is a novel, once-daily orally active, first-in-class, potent β_3 -adrenoreceptor (AR) agonist. **Aim of the study:** This work aimed at exploring the possible prophylactic effect of mirabegron on non-alcoholic steatohepatitis (NASH) induced experimentally by high fat diet in rats. **Material and methods:** Rats were divided into 5 groups: Control normal group, Mirabegron group, Untreated NASH group (received a high fat diet for 12 weeks), Low dose mirabegron pre-treated NASH group (treated with mirabegron 5 mg/kg/day orally for 12 weeks) and High dose mirabegron pre-treated NASH group (treated with mirabegron 10 mg/kg/day orally for 12 weeks). **Results:** Mirabegron produced significant reduction of liver enzymes (GGT, AST, ALT), total cholesterol, triglycerides and LDL-c and significant elevation of HDL-c, Also the serum level of HbA1c, fasting glucose and insulin levels were significantly decreased with significant improvement of insulin sensitivity observed by lowering of insulin resistance index (HOMA-IR), serum adiponectin level also showed significant elevation. These results were supported by marked improvement of liver histopathology compared to non-treated NASH group, with the best results obtained by using the high dose of mirabegron (10 mg /kg/day).

Key words: Non-alcoholic fatty liver disease, high fat diet and Mirabegron.

Introduction

Non-alcoholic fatty liver disease (NAFLD) is an increasingly recognized as one of the most common causes of chronic liver disease worldwide that may progress to end stage liver disease.¹ Non-alcoholic steatohepatitis (NASH) is typically characterized by liver steatosis, inflammation and fibrosis driven by metabolic disruptions such as obesity, diabetes and dyslipidemia. Within this spectrum, steatosis alone

is apparently benign, while non-alcoholic steatohepatitis may progress to cirrhosis, hepatocellular carcinoma and liver failure. ² Despite extensive research over the past decades, the pathogenesis of NAFLD is not entirely understood, and treatment of this disease has not been fully defined. It has been suggested that the development of steatohepatitis is a consequence of the balance between pro and anti-inflammatory effects of adipokines (e.g., adiponectin, resistin, visfatin and leptin).³ Mirabegron is the first β_3 -adrenoreceptor (AR) agonist which was approved for the treatment of overactive bladder (OAB) in the United States, Japan, the European Union and Canada.⁴ Many researches demonstrated that β_3 -AR stimulation resulted in activation of human brown adipose tissue (BAT) in healthy male subjects. ⁵ Thereby, it could be expected that chronic administration of β_3 -AR agonist may result in activation of thermogenic tissues with all subsequent beneficial metabolic consequences. ⁶ Nevertheless, these aspects were not studied in trials of mirabegron in the treatment of OAB.

MATERIALS AND METHODS

Animals: 36 Adult male albino rats (brought from Vacsera-Cairo) weighing between 150-180 g (at the beginning of the study), were used for in-vivo experiments. They have acclimatized for one week and were caged in fully ventilated room (at temperature ranging from 25-30°C). Food and water were provided ad libitum.

Type of study: *Prospective*

Duration: *5/1/2021 to 5/4/2021*

Place: *pharmacology department - benha faculty of medicine*

Ethical consideration:

Experimental rats should be under complete healthy conditions all over the experiment in the form of:

- Clean environment.
- Good ventilation.
- Good nutrition.
- Number of rats in each cage is six.

- The experimental rats will be under care of a professional technician and a qualified researcher.

At the end of the study the rats were anaesthetized, sacrificed and disposed to Benha university hospital incinerator.

Drugs and chemicals:

Mirabegron (Astellas, Japan, Egypt), Cholesterol (powder): El Naser Pharmaceutical chemicals, Hematoxylin and eosin,Urethane (Ethyl carbamat):(white crystals).

Mirabegron was dissolved in distilled water.⁷

Induction of NASH:

NASH was induced by high fat diet formed of a laboratory chow diet in addition to 10% animal fat, 2% cholesterol, and 5% corn oil for 12 weeks.⁸

*** Animal groups:-**

Rats were divided into five groups: Group I (Control normal group): received a standard chow diet and tap water with no medication, Group II (Mirabegron group):subdivided into: Subgroup IIa: received a standard chow diet and tap water with oral administration of mirabegron (5 mg/kg /day) for 12 weeks⁹ and Subgroup IIb: received a standard chow diet and tap water with oral administration of mirabegron (10 mg/kg /day) for 12 weeks¹⁰, Group III (Untreated NASH group): received a high fat diet for 12 weeks with no medication⁸, Group IV (Low dose mirabegron pre-treated NASH group): received a high fat diet with oral administration of mirabegron at a dose of (5 mg/kg/day) for 12 weeks⁹ and Group V (High dose mirabegron pre-treated NASH group): received a high fat diet with oral administration of mirabegron at a dose of (10 mg/kg/day) for 12 weeks.¹⁰

Sample collection

At the end of the experiment (12 weeks), rats were overnight fasted for 12 hours, rats were anesthetized with urethane a dose of 0.6 ml/100

gm BWT of 25% fresh prepared solution¹¹ and then were fixed on operating table and the blood samples were taken as following: Ventral thoracic incision of about 2 cm was made, parallel and slightly to the left of the sternum through the skin and pectoral muscles to expose the ribs. The gap was widened so that the rapidly beating heart becomes visible, then the blood sample was taken from the heart by syringe. Samples for biochemical analysis of liver enzymes, lipid profile and insulin levels were incubated at 37°C until blood clotted and then centrifuged at 3000 revolution per minute (rpm) for 15 min for separation of serum and stored at – 20° C at refco deep freeze.¹²

1-Determination of liver function tests: were performed on samples by colorimetric methods (GGT, AST, ALT), by using GGT, ALT and AST kit (Human , Egypt), according to the method of Reitman and Frankel.¹³

2-Determination of serum lipid profile: Serum levels of total cholesterol (TC), triglyceride (TG) and high- density lipoprotein-cholesterol (HDL-C) were determined using colorimetric enzymatic kits (Bio Diagnostic, Dokki, Egypt) according to the manufacturer's instructions.^{14, 15, 16} Low-density lipoprotein cholesterol (LDL-C) was calculated using the Friedewald formula [LDL- cholesterol= Total Cholesterol- (HDL-cholesterol+ TG/5) (mg/dl)].¹⁷

3-Measurement of fasting blood glucose:

Fasting blood glucose was measured on a Beckman Glucose Analyzer II (Beckman, Fullerton, CA).¹⁸

4-Measurement of fasting insulin level: by rat insulin ELISA kit (SunLong Biotech Co., LTD).¹⁹

5-Insulin resistance by HOMA-IR index: Insulin resistance was measured using the homeostasis model assessment (HOMA-IR) defined by the following formula:²⁰

HOMA-IR= Fasting glucose level (mg/dl) x Fasting insulin level (µIU/mL) /405.

6-Measurement of HbA1c: by Rat HbA1c (Glycosylated Hemoglobin/Hemoglobin A1c) ELISA Kit using Sandwich ELISA as the method. ²¹

7- Measurement of serum adiponectin level: using Adiponectin rat ELISA kits (Biovendor,Germany),This ELISA kit uses Sandwich ELISA as the method. ²²

Histopathology of the liver:

After functional studies were completed, the liver of rats were put into a buffered 4% formaline fixation solution and processed with paraffin wax for histopathological examination. Sections (5 μ m) were stained with hematoxylin and eosin. ²³

Statistical analysis: In the statistical comparison between the different groups, the significance of difference was tested using ANOVA test (F value):-Used to compare mean of more than two groups of quantitative data using multiple comparison post hoc test (LSD). *P* value <0.05 was considered statistically significant while >0.05 statistically insignificant *P* value <0.01 was considered highly significant.

RESULTS

There was no significant difference between subgroup IIa and subgroup IIb in all parameters, so all statistical comparisons were compared to subgroup IIb as mirabegron group.

In mirabegron group, there was insignificant difference ($p>0.05$) in all parameters including:, liver enzymes (AST, ALT and GGT), lipid profile (TC, TG, LDL-C and HDL-C), fasting glucose and insulin levels, HBA1c, insulin sensitivity and serum adiponectin levels when compared to control group.

Induction of NASH by high fat diet resulted in significant elevation in liver enzymes (AST, ALT and GGT), TC, TG, LDL-C, fasting glucose and insulin levels, HBA1c and insulin sensitivity with significant reduction of HDL-C and serum adiponectin level in untreated NASH group when compared to control group.

Treatment with two different doses of mirabegron resulted in significant reduction of liver enzymes (AST, ALT and GGT), TC, TG,

LDL-C, fasting glucose and insulin levels, HBA1c with improvement of insulin sensitivity observed by lowering of HOMA-IR index. The serum HDL-C and adiponectin levels were significantly elevated in treated groups when compared to untreated NASH group. Although the two doses of mirabegron produced improvement in all of these parameters, the high dose of mirabegron produced the best results.

Microscopic examination of liver sections of rats of control and mirabegron groups displayed normal liver architecture (figure 1,2). Rats of untreated-NASH group showed severe steatosis, hepatocyte ballooning and degeneration with multiple foci of inflammatory cell infiltration (figure 3). whereas, hepatocyte ballooning and degeneration and the infiltration of inflammatory cells were markedly ameliorated in low dose mirabegron pretreated group and high dose mirabegron pretreated group (figure 4,5). However high dose mirabegron pretreated group exhibited better improvement of liver architecture.

Parameters mean ± SD			
Groups	AST(U/L)	ALT(U/L)	GGT (U/L)
Group I: Control Group	102.00±9.63	46.5±3.8	8.92±0.34
Group II: Mirabegron group	105.33±7.67	48.71±3.19	9.08±0.71
Group III: Untreated NASH Group	164.64± 14.4 ^{a,b}	93.33± 9.5 ^{a,b}	26.36± 1.83 ^{a,b}
Group IV: Low dose mirabegron pre-treated Group	136.00± 8.22 ^{a,b,c}	65± 3.95 ^{a,b,c}	16.78± 0.71 ^{a,b,c}
Group V: high dose mirabegron pre-treated Group	109.5 ± 7.9 ^{c,d}	54± 3.6 ^{a,b,c,d}	12.18± 0.43 ^{a,b,c,d}

Table (1): Effect of pre-treatment with mirabegron (5 mg/kg/day and 10mg/kg/day p.o for 12 weeks) on liver enzymes in a model of NASH (induced by 10% animal fat, 2% cholesterol, and 5% corn oil for 12 weeks) in adult male albino rats.

Data are presented as mean (M) ± SD

a: Significant difference versus control at $p < 0.05$.

b: Significant difference versus untreated mirabegron group at $p < 0.05$

c: Significant difference versus untreated NASH group at $p < 0.05$

d: Significant difference versus low dose mirabegron pretreated NASH group at $p < 0.05$.

Groups	Parameters mean ± SD			
	Total cholesterol (mg/dl)	Triglyceride (mg/dl)	LDL-c (mg/dl)	HDL-c (mg/dl)
Group I: Control Group	110.83±6.55	116.76±7.09	40.76±4.91	47.66±2.36
Group II: Mirabegron group	114.17±9.87	113.79±5.02	43.27±11.05	45.75±2.81
Group III: Untreated NASH Group	292.32± 15.02 ^{a,b}	246.72± 21.9 ^{a,b}	215.48±24.61 ^{a,b}	27.7±1.89 ^{a,b}
Group IV: Low dose mirabegron pre-treated Group	150.83± 9.81 ^{a,b,c}	167.04± 8.23 ^{a,b,c}	76.3 ± 10.2 ^{a,b,c}	41.05±1.83 ^{a,b,c}

Group V: high dose mirabegron pre-treated Group	127.17± 8.51 ^{a,b,c,d}	136.59± 7.98 ^{a,b,c,d}	54.1± 14.57 ^{a,c,d}	46.2±2.68 ^{c,d}
--	---------------------------------	---------------------------------	------------------------------	--------------------------

Table (2): Effect of pre-treatment with mirabegron (5 mg/kg/day and 10 mg/kg/day p.o for 12 weeks) on lipid profile in a model of NASH (induced by 10% animal fat, 2% cholesterol, and 5% corn oil for 12 weeks) in adult male albino rats.

Data are presented as mean (M) ± SD

a: Significant difference versus control at p<0.05.

b: Significant difference versus untreated mirabegron group at p<0.05

c: Significant difference versus untreated NASH group at p<0.05

d: Significant difference versus low dose mirabegron pretreated NASH group at p<0.05

Groups	Parameters mean ± SD			
	FBG (mg/dl)	Fasting insulin (uU/ml)	HOMAIR index	HbA1c (ng/ml)
Group I: Control Group	89.23±3.45	9.09±1.82	1.96±0.59	11.82±0.69
Group II: Mirabegron group	86.92±3.14	8.31± 1.95	1.8±0.49	12.04±1.04
Group III: Untreated NASH Group	211.24± 12.04 ^{ab}	22.33± 2.81 ^{a,b}	11.96± 2.91 ^{a,b}	18.32±0.59 ^{a,b} ↓

Group IV: Low dose mirabegron pre-treated Group	154.38±5.8 ^{a,b,c}	17.58± 1.37 ^{a,b,c}	6.45± 0.90 ^{a,b,c}	14.81±0.33 ^{a,b,c}
Group V: high dose mirabegron pre-treated Group	120.7 ± 5.34 ^{a,b,c,d}	± 1.74 ^{a,b,c,d} 13.22	3.76± 0.63 ^{a,b,c,d}	13.84±0.52 ^{a,b,c,d}

Table (3): Effect of pre-treatment with mirabegron (5 mg/kg/day and 10 mg/kg/day p.o for 12 weeks) on FBG, fasting insulin, HOMA-IR index and HbA1c levels in a model of NASH (induced by 10% animal fat, 2% cholesterol, and 5% corn oil for 12 weeks) in adult male albino rats. Data are presented as mean (M) ± SD

a: Significant difference versus control at p<0.05.

b: Significant difference versus untreated mirabegron group at p<0.05

c: Significant difference versus untreated NASH group at p<0.05

d: Significant difference versus low dose mirabegron pretreated NASH group at p<0.05

Group	Serum adiponectin level (ng/ml)
Group I: Control Group	28.67±1.43
Group II: Mirabegron group	30.27±2.6
Group III: Untreated NASH Group	10.48 ±0.85 ^{a,b}
Group IV: Low dose mirabegron pre-treated Group	17.63 ±1.56 ^{a,b,c}
Group V: high dose mirabegron	22.67±0.75 ^{a,b,c,d}

pre-treated group	
--------------------------	--

Table (4): Effect of pre-treatment with mirabegron (5 mg/kg/day and 10 mg/kg/day p.o for 12 weeks) on the serum level of adiponectin in a model of NASH (induced by 10% animal fat, 2% cholesterol, and 5% corn oil for 12 weeks) in adult male albino rats.

Data are presented as mean (M) \pm SD

a: Significant difference versus control at $p < 0.05$.

b: Significant difference versus untreated mirabegron group at $p < 0.05$

c: Significant difference versus untreated NASH group at $p < 0.05$

d: Significant difference versus low dose mirabegron pretreated NASH group at $p < 0.05$

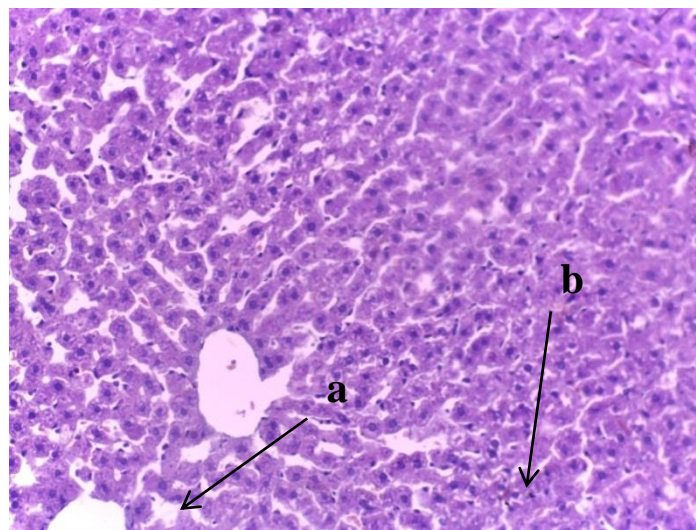


Figure (1): A photomicrograph of a cut section in the liver of a control rat (group I) showing: (a) normal central vein (b) normal hepatocytes (H&Ex40).

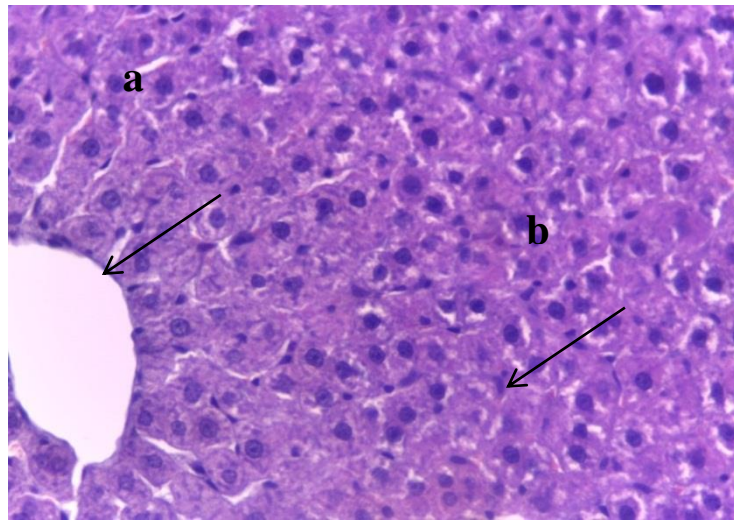


Figure (2): A photomicrograph of a cut section in the liver of a rat in mirabegron group (group II) showing: (a) normal central vein(b) normal hepatocytes (H&Ex40).

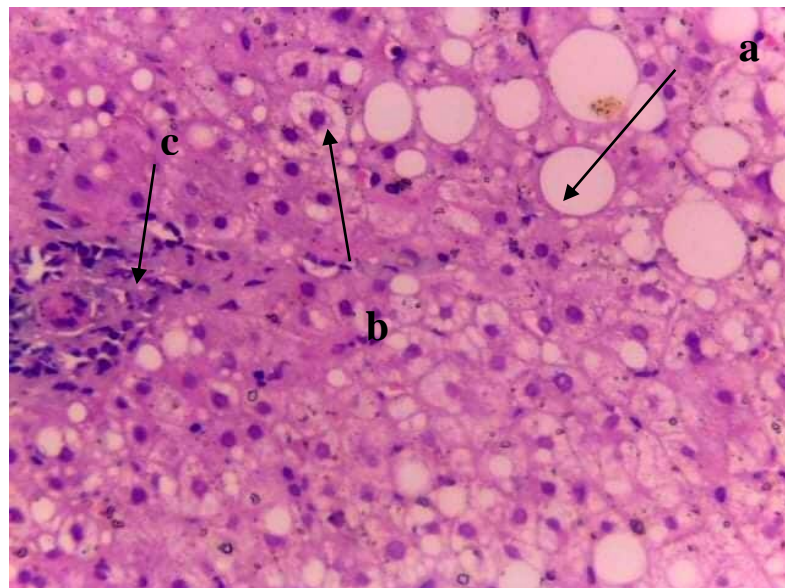
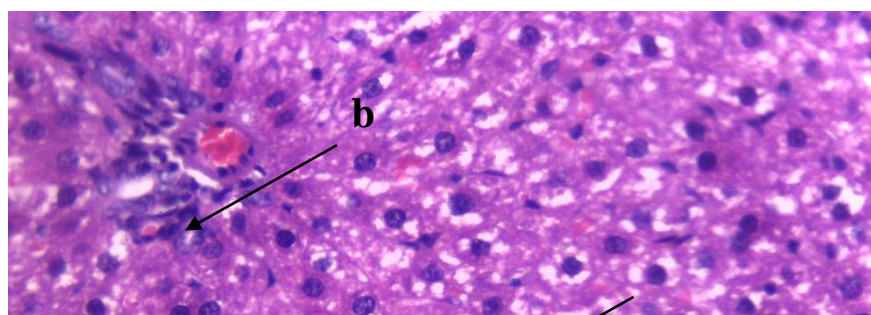


Figure (3): A photomicrograph of a cut section in the liver of fatty untreated rat (group III) showing: severe (a) steatosis, (b) ballooning and (c) inflammatory cell infiltration (H&Ex40).



a

Figure (4): A photomicrograph of a cut section in the liver of low dose mirabegron treated rat (group IV) showing: moderate (a) ballooning and (b) inflammatory cell infiltration (H&Ex40).

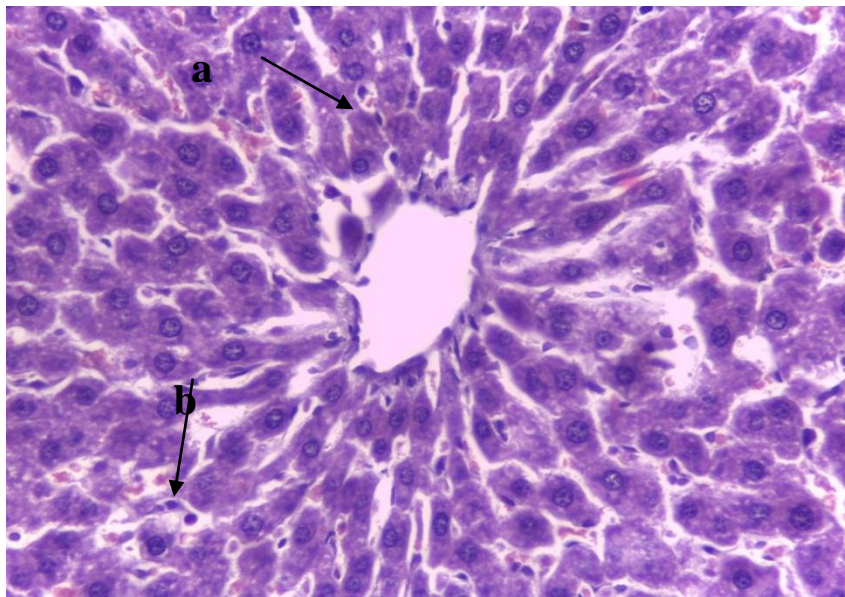


Figure (5): A photomicrograph of a cut section in the liver of high dose mirabegron treated rat (group V) showing: mild (a) ballooning and mild (b) inflammatory cell infiltration (H&Ex40).

Discussion

Chronic liver disease (CLD) is a major cause of mortality, morbidity and health care resource utilization worldwide.²⁴ Non-alcoholic fatty liver disease (NAFLD) is an increasingly recognized as one of the leading causes of chronic liver disease worldwide that may progress to end stage liver disease.²⁵

Non-alcoholic fatty liver disease is frequently associated with the metabolic syndrome including diabetes mellitus, hypercholesterolemia, hypertension and obesity.²⁶ All of these complications of NASH can pose significant health, economic, and patient-experience burdens to the patients.²⁷

Mirabegron is a novel, once-daily orally active, first-in-class, potent β_3 adrenoreceptor (β_3 AR) agonist.^{28,29} The β_3 -adrenoceptor is the predominant β -adrenoceptor in white and brown adipocytes, where its activation results in increased lipolysis in white adipocytes and increased thermogenesis in brown adipocytes. Recently, the role of these adrenoreceptors in brown adipose tissue (BAT) has regained attention.³⁰

In this study, NASH model was induced in rats by high fat diet (HFD) formed of a laboratory chow diet in addition to 10% animal fat, 2% cholesterol, and 5% corn oil for 12 weeks.⁸ This NASH rat model closely resembles the pathophysiology observed in human NASH.³¹

The data of the present work revealed that 12 weeks of high fat diet administration resulted in significant elevation in liver enzymes (GGT, AST and ALT), also lipid profile showed significant increase in triglycerides, total cholesterol and LDL-C with significant decrease in HDL-C. Histopathological examination revealed hepatic alteration in the form of steatosis, hydropic degeneration and inflammatory cell infiltration. These results were in agreement with *Olorunnisola et al.* and *Kumar et al.*^{32,33}; they reported that dyslipidemia induced by ingestion of high fat diet is the primary cause of lipid peroxidation and decrease the strength of the antioxidative defenses. Also *Goorani et al.* and *Anekwe et*

al. ^{34,35} reported that hepatic steatosis induced by high fat diet induced elevation of liver enzymes (GGT, AST, ALT) , alteration in lipid profile (elevation of triglyceride, cholesterol and LDL-C and decrease in HDL-C).

Estimation of the activity of ALT, AST and GGT are good markers of assessment. These enzymes are normally located in the cytosol of hepatocytes. When liver cells are damaged, these enzymes are released in the plasma and increased their activity in plasma is a useful marker of the extent and type hepatocellular damage. ^{36,37}

Results obtained from this study showed that, serum levels of triglycerides, total cholesterol, and LDL-C were significantly elevated while HDL-C was significantly reduced in rats fed on HFD; this is consistent with *Tourkostani et al.* and *Ilmiawati et al.* ^{38,39.}

Feeding of high fat diet results in excess hepatic triglycerides accumulation due to increased synthesis and decreased secretion of triglycerides and increased de novo lipogenesis ⁴⁰ and induce oxidative stress in various organs such as the liver, heart, and aorta ^{41,42}

In the current study, serum level of HbA1c, fasting glucose and insulin levels were significantly elevated with increased insulin resistance index (HOMA-IR) in rats fed on HFD; this is consistent with *Abd Allah et al. and Al Mamun et al.* ^{43,44} , who reported that ingestion of HFD resulted in NAFLD with subsequent hyperglycemia, hyperinsulinemia and high insulin resistance.

It has been considered that insulin resistance and hyperinsulinemia play a key role in the pathogenesis of NALFD. Excessive deposition of fat in adipocytes and muscles determines insulin resistance with subsequent accumulation of fat in the liver, which, in turn, increases the rate of mitochondrial beta-oxidation of fatty acids and ketogenesis that can promote lipid peroxidation and accumulation of reactive oxygen species (ROS) in the hepatocytes. ⁴⁵

Results of the present study revealed significant lowering of serum adiponectin level in rats fed on high fat diet, which is in agreement with many prious reseaches. ^{46,47}

Adiponectin is one of the several hormones secreted by adipose tissue known collectively as adipocytokines. In a healthy liver, adiponectin regulates the metabolism of glucose and lipids, decreasing gluconeogenesis and stimulating glycolysis and fatty acid oxidation ^{48,49}. The model of HFD-induced NAFL in rats performed by *Ahmed et al.* ⁵⁰ also showed induced inflammatory state as elevated serum TNF- α and decreased adiponectin level with impaired insulin signaling, oxidative stress, and inflammatory responses in hepatic and adipose tissues. Data of the present study showed that treatment of high fat diet fed rats with mirabegron in two different doses (5 mg/kg/day and 10 mg/kg/day) for 12 weeks resulted in significant improvement of elevated liver enzymes (GGT, AST and ALT) compared to non-treated group with best results obtained by using high dose (10 mg/kg). These results are in line with *Elbadr and Elbadre* ⁵¹, who reported that treatment with mirabegron improved hepatic function parameters (AST and ALT) due to its antioxidant properties as it decreased MDA and increased GSH serum levels. *Poekes et al.* ⁵² found that mirabegron decreased serum transaminases levels in high fat diet fed mice with significant lowering of hepatocyte ballooning and inflammation in mirabegron-treated livers as well as in collagen 1 expression..

Results of the current study revealed that treatment of high fat diet fed rats with two different doses of mirabegron resulted in dose related improvement of lipid profile (lowering of total cholesterol, triglycerides and LDL-C and elevation of HDL-C serum levels) compared to non-treated rats. Also the serum levels of HbA1c, fasting plasma insulin and blood glucose were significantly decreased with significant improvement of insulin sensitivity observed by lowering of insulin resistance index (HOMA-IR) in groups treated by two doses of mirabegron with the best results obtained by using the high dose of mirabegron (10 mg/kg/day).

These data are supported by several previous studies as *Finlin et al.* ⁵³ who reported that treatment of obese humans with mirabegron improved oral glucose tolerance test, HbA1c, and insulin sensitivity, stimulated lipolysis, and reduced fibrotic gene expression with a trend towards decreased total cholesterol levels and significant reduction of triglycerides.

These data also are in consistence with *Calmasini et al.*⁵⁴ who concluded that high fat diet fed mice treated by mirabegron 10 mg/kg/day exhibit significant reduction of epididymal fat and serum LDL-C with elevation of serum HDL-C level.

Mirabegron treatment ameliorated BAT “whitening” caused by HFD feeding and enhanced beige adipocyte, brown-like adipocytes found in white adipose tissue (WAT) formation.^{55,56,57}

Many studies reported that treatment with β 3AR agonist restored BAT function, decreased body weight, improved glucose tolerance and insulin sensitivity, and reduced hepatic lipid content compared to untreated counterparts in high fat diet fed animals. When BAT is stimulated chronically, it consumes triglyceride-rich (TG-rich) lipoproteins and subsequently generates HDL cholesterol so BAT activation is able to correct hyperlipidemia and improves the deleterious effects of obesity.^{58,52,59}

We found in this study that high fat diet fed rats treated with two doses of mirabegron showed significant elevation of serum adiponectin level with the best results obtained from high dose. *Berbee et al. and Cypess et al.*^{60,61} showed that chronic activation of brown fat by mirabegron leads to many metabolic benefits, including increased energy expenditure, improved cholesterol profile and insulin sensitivity stimulated the release of brown adipokines as adiponectin helping other tissues consume fatty acids and glucose and attenuated the development of atherosclerosis.

Adiponectin has anti-diabetic, antiatherogenic, anti-inflammatory and insulin-sensitizing properties.⁶² Adiponectin through its receptors usually activates different molecular pathways. Adiponectin activating AMP and P38 kinases in skeletal muscle and liver tissues, stimulates phosphorylation of acetyl coenzyme-A carboxylase (ACC) and PPAR- α , fatty acid oxidation, and glucose uptake via increasing GLUT-4 translocation in muscle cells. Through these pathways, Adiponectin mainly exerts its insulin-sensitizing actions.^{63,64} Adiponectin induces an up-regulation of the anti-inflammatory cytokine IL-10 and interleukin-1 receptor antagonist (IL-1RA) expression.⁶⁵ Furthermore, it inhibits the production of inflammatory cytokines and adhesion molecules reducing

the inflammatory state in the various cellular models. This adipokine has been shown to inhibit (TNF- α)-induced nuclear factor-kB activation in endothelial and epithelial cells.⁶⁶

Histopathological examination supported the biochemical analysis. It was found that, rats fed on high fat diet for 12 weeks showed severe histopathological NASH lesions (including steatosis, ballooning degeneration and inflammation), this coincides with many previous results.^{67,68}

Histopathological examination of the liver of treated groups supported the previous results. It was found that, liver of mirabegron pre-treated rats showed mild ballooning degeneration and inflammatory cell infiltration without steatosis, this coincides with *Wang et al.*⁶⁹ who found that β 3 adrenoceptor activation in HFD fed rats ameliorated liver steatosis, inflammation and hepatocyte ballooning degeneration with significant improvement of liver enzymes (AST and ALT), TGs, TC and LDL-C. These protective effects were due to inhibition of mitochondrial ultrastructural damage in the liver of HFD rat and regulated the expression of peroxisome proliferator-activated receptors (PPARs). PPAR- α regulates the expression of various genes responsible for lipid metabolism that are also responsible for FA uptake, FA oxidation, cell generation, TG processing and lipid droplet formation and decomposition.⁷⁰

Conclusion:

In our study, it was found that mirabegron affords hepatoprotective effects as regard to liver enzymes, total cholesterol, triglycerides, LDL-C, HDL-C, serum HbA1c, fasting insulin and blood glucose, insulin resistance index (HOMA-IR), and serum adiponectin levels with improvement of histopathological changes of the liver.

References:

- 1- Grgurevic, I.; Podrug, K.; Mikolasevic, I. et al., (2020):** Natural History of Nonalcoholic Fatty Liver Disease: Implications for Clinical Practice and an Individualized Approach. *Canadian Journal Of Gastroenterology And Hepatology*; 45(4).

- 2- **Peng, C.; Stewart, A.; Woodman, O. et al., (2020):** Non-Alcoholic Steatohepatitis: A Review of Its Mechanism, Models and Medical Treatments. *Front. Pharmacol.*; 12:77.
- 3- **Jamali, R.; Arj, A.; Razavizade, M.; Aarabi, M.H.(2016):** Prediction of nonalcoholic fatty liver disease via a novel panel of serum adipokines. *Medicine.*;95(5):2630.
- 4- **Leone, M. U.; Cardozo, L. AND Ferrero ,S.(2014):** Mirabegron in the treatment of overactive bladder. *Expert Opin Pharmacother.*;15:873–887.
- 5- **Cypess, A.M.; Weiner, L.S.; Roberts-Toler, C. et al., (2015):** Activation of human brown adipose tissue by a β 3-adrenergic receptor agonist. *Cell metabolism*, 21(1), 33–38.
- 6- **Krhut, J.; Borovička, V.; Bílková, K. et al., (2018):** Efficacy and safety of mirabegron for the treatment of neurogenic detrusor overactivity prospective, randomized, double-blind, placebo-controlled study. *Neurourol Urodyn* 37:2226–2233.
- 7- **An, J.H.; Lim, C.; Kiyonga, A.N.; Chung, I.H.; Lee, I.K. et al., (2018):** Co-Amorphous Screening for the Solubility Enhancement of Poorly Water-Soluble Mirabegron and Investigation of Their Intermolecular Interactions and Dissolution Behaviors. *Pharmaceutics*. 5;10(3):149.
- 8- **Wang, W.; Zhao, C.; Zhou, J.; Zhen, Z.; Wang, Y.; Shen, C. (2013):** Simvastatin ameliorates liver fibrosis via mediating nitric oxide synthase in rats with non-alcoholic steatohepatitis-related liver fibrosis. *PLoSOne*. ;8: 76538.
- 9- **Doghri, Y.; Lalanne, V.; Mallem, Y. et al., (2018):** Chronic treatment with Mirabegron improves cardiovascular reactivity in spontaneously hypertensive rats with metabolic syndrome, *Archives of Cardiovascular Diseases Supplements*,; 10 : 2.
- 10- **Calmasini, F.; De Oliveira, M.; Alexandre, E. et al., (2016):** Long-term treatment with the beta-3 adrenoceptor agonist, mirabegron ameliorates detrusor overactivity and restores cyclic adenosine monophosphate (cAMP) levels in obese mice. *Neurourology and urodynamics*; 16(9):15.
- 11- **Ofem, O.E.; Eno, A.E. and Antai, A.B. (2012):** Gastric acid anti-secretory, anti-ulcerogenic and mucogenic effects of aqueous

leaves extract of *Ocimum gratissimum* in rats. *Niger. J. Physiol. Sci.*, 27: 041– 047 .

- 12- **Parasuraman, S.; Raveendran, R. and Kesavan, R. (2010):** Blood sample collection in small laboratory animals. *J. Pharmacol. Pharmacother*; 1: 87–93.
- 13- **Reitman, S. and Frankel, S. (1975):** Colorimetric method for determination of serum glutamic oxalatacetic and glutamic pyruvic transaminases. *Am J Clin Pathol.*, 28:56-63.
- 14- **Fossati, P. (1982):** Enzymatic determination of serum triglycerides. *Principle Clin. Chem*; 28: 2077.
- 15- **Siedel, J.H.; Schlumberger, S.; Klose, J. and Washlefeld, A.W. (1991):** *J. Clin. Chem. Clin. Bioch*; 19: 838. quoted from Boehringer Mannheim GMBH Diagnostic Manual.
- 16- **Lopes–Virella, M.F.; Stone, P.; Ellis, S. and Colwell, J.A. (1977):** Cholesterol determination in high-density lipoproteins separated by three different methods. *Clin. chem*; 23 (5): 882-4.
- 17- **Friedewald, W.T.; Levy, R.I. and Fredrickson, D.S. (1972):** Estimation of the concentration of low-density lipoprotein cholesterol in plasma, without use of the preparative ultracentrifuge. *Clin. Chem*; 18: 499-512.
- 18- **Efendic, S.; Karlander, S. and Vranic, M. (1988):** Mild type II diabetes markedly increases glucose cycling in the postabsorptive state and during glucose infusion irrespective of obesity. *J Clin Invest.*, 81: 1953-1961.
- 19- **Gerard, D.; Angelo, A.; David, M. and David, W. (2005):** Fructose Feeding Increases Insulin Resistance but Not Blood Pressure in Sprague-Dawley Rats. *Hypertension*, 46:806.
- 20- **Matthews, D. R.; Hosker, J. P.; Rudenski, A. S.; Naylor, B. A.; et al., (1985):** Homeostasis model assessment :insulin resistance and beta-cell function from fasting plasma glucose and insulin concentration in man. *Diabetologia.*, 28:412-419.
- 21- **Miedema, K. (2005):** Standardization of HbA1c and Optimal Range of Monitoring. *Scand J Clin Lab Invest* 240: 61-72.
- 22- **Garcés-Rimón, M.;González, C; Uranga-Ocio, J.; Lopez, M. et al., (2016):** Pepsin Egg White Hydrolysate Ameliorates Obesity-Related Oxidative Stress, Inflammation and Steatosis in Zucker Fatty Rats. *PloS one*;11(3): 1371.

- 23- **Drury, R.A.B. and Wallington, E.A. (1967):** Carleton's histological techniques. Oxford University Press, New York.
- 24- **Marcellin, P. and Kutala, B.K. (2018):** Liver diseases: a major, neglected global public health problem requiring urgent actions and large-scale screening. *Liver Int.* ; 38: 2-9.
- 25- **Maurice, J. and Manousou, P. (2018):** Non-alcoholic fatty liver disease. *Clin Med (Lond)*. 2018 Jun;18(3):245-250.
- 26- **Younossi, Z.M.; Marchesini, G.; Pinto-Cortez, H. and Petta, S. (2019):** Epidemiology of nonalcoholic fatty liver disease and nonalcoholic steatohepatitis. *Transplantation*, vol. 103, no. 1, pp. 22–27.
- 27- **Younossi, Z.; Tacke, F.; Arrese, M. et al., (2018):** Global perspectives on non-alcoholic fatty liver disease and non-alcoholic steatohepatitis. *Hepatology*.;70 (3):P531-544.
- 28- **Takasu, T.; Ukai, M.; Sato, S. et al., (2007):** Effect of (R)-2-(2-aminothiazol-4-yl)-4'-2-[(2-hydroxy-2-phenylethyl)amino]ethyl acetanilide (YM178), a novel selective β 3-adrenoceptor agonist, on bladder function. *J Pharmacol Exp Ther.* ; 321: 642-647.
- 29- **Hatanaka, T.; Ukai, M.; Watanabe, M. et al., (2013):** Pharmacological profile of the selective β 3-adrenoceptor agonist mirabegron in cynomolgus monkeys. *Naunyn Schmiedebergs Arch Pharmacol* 386: 1001–1008.
- 30- **Muzik, O.; Mangner, T.J.; Leonard, W.R.; Kumar, A.; Janisse, J. and Granneman, J.G. (2013):** 15O PET measurement of blood flow and oxygen consumption in cold-activated human brown fat. *J Nucl Med*.;54:523–531.
- 31- **Teratani, T.; Tomita, K.; Suzuki, T. et al., (2012):** A high-cholesterol diet exacerbates liver fibrosis in mice via accumulation of free cholesterol in hepatic stellate cells. *Gastroenterology*.;142:152-64.
- 32- **Olorunnisola, O.S.; Bradley, G. and Afolayan, A.J. (2012):** Protective effect of *T. violacea* rhizome extract against hypercholesterolemia-induced oxidative stress in wistar rats. *Molecules*. 17: 6033-6045.
- 33- **Kumar, P.; Bhandari, U. and Jamadagni, S.H. (2014):** Fenugreek seed extract inhibits fat accumulation and ameliorates dyslipidemia in high fat diet-induced obese rats. *BioMed Research International*. Volume 2014, 11 pages.

- 34- **Goorani, S.; Zhaleh, M.; Hajialiani, M. et al., (2019):** Hepatoprotective potential of aqueous extract of *Allium eriophyllum* Boiss in high-fat diet-induced fatty liver diseases. *Comparative Clinical Pathology*; 28, pages963–969.
- 35- **Anekwe, C.V.; Chandrasekaran, P.; Stanford, F. C. (2020):** Ketogenic Diet-induced Elevated Cholesterol, Elevated Liver Enzymes and Potential Non-alcoholic Fatty Liver Disease. *Cureus* 12(1): e6605.
- 36- **Helal, E.G.; Abd El-Wahab, S.M.; Sharaf A.M. and Zedan, G.A. (2012):** Effect of *Zingiber officinale* on fatty liver induced by oxytetracycline in albino rats. *The Egyptian Journal of Hospital Medicine* ;46: 26 – 42.
- 37- **Liu, L.; Zhou, Y.; Hongmei, D.D. et al.,(2018):** Protective effects of Kangxian ruangan capsule against nonalcoholic fatty liver disease fibrosis in rats induced by MCD diet. *Biomedicine & Pharmacotherapy*;108: 424-434.
- 38- **Tourkostani, R.; Al Balouni, I.A.; Moselhy, S.S. and Kumosani, T.A. (2009):** A diet rich fiber improves lipid profile in rats fed on high fat diet. *Turk J. Biochem*; 34 (2): 105–111.
- 39- **Ilmiawati, C.; Fitri, F.; Rofinda, Z. et al., (2020):** Green coffee extract modifies body weight, serum lipids and TNF- α in high-fat diet-induced obese rats. *BMC Research Notes*; 13(10):34-42.
- 40- **Liu, C.H.; Huang, M.T. and Huang, P.C. (1995):** Sources of triacylglycerol accumulation in livers of rats fed a cholesterol supplemented diet. *Lipids*. 30 (6): 527–531.
- 41- **Dutta, K. and Bishayi, B. (2009):** *Escherichia coli* lipopolysaccharide administration alters antioxidant profile during hypercholesterolemia. *Indian J. Clin. Biochem*; 24: 179–183.
- 42- **Vargas-Robles, H.; Rios, A.; Arellano-Mendoza, M. et al., (2015):** Antioxidative Diet Supplementation Reverses High-Fat Diet-Induced Increases of Cardiovascular Risk Factors in Mice. *Oxidative Medicine and Cellular Longevity*; 16(9).
- 43- **Abd Allah, O.M. (2017):** Beneficial effects of diacerein on adipokines and pro-inflammatory cytokines involved in diet-induced non alcoholic steatohepatitis in rat. *Int J Basic Clin Pharmacol.* ;6(4):811-820.

- 44- **Al Mamun, A.; Faruk T.; Rahman, M. et al., (2019):** High Carbohydrate High Fat Diet Induced Hepatic Steatosis and Dyslipidemia Were Ameliorated by Psidium guajava Leaf Powder Supplementation in Rats", Evidence-Based Complementary and Alternative Medicine; 2019: 12 .
- 45- **Albano. E. ; Mottaran, M. ; Vidali, L. et al., (2005):** Immune response towards lipid peroxidation products as a predictor of progression of non-alcoholic fatty liver disease to advanced fibrosis," Gut; 54, no. 7, pp. 987–993.
- 46- **Song, L.; Qu, D.; Zhang, Q. et al., (2017):** Phytosterol esters attenuate hepatic steatosis in rats with non-alcoholic fatty liver disease rats fed a high-fat diet. Sci Rep ;7: 41604.
- 47- **Kandil, Y. and Oriquat, G.A. (2019):** Adiponectin mediates the hypolipidemic effect of Spirulina against experimentally-induced non-alcoholic fatty liver in rats. Egyptian Liver Journal 8(4):126-131.
- 48- **Mao, X.; Kikani, C.K.; Riojas, R.A. et al., (2006):** APPL1 binds to adiponectin receptors and mediates adiponectin signalling and function. Nat Cell Biol ; 8:516–523.
- 49- **Lee, B. and Shao, J. (2012):** Adiponectin and lipid metabolism in skeletal muscle. Acta Pharmaceutica Sinica B; 2(4): 335-340.
- 50- **Ahmed, N.M.; Helmy, M.H.; Kamel, M.A. and Hanafy, M.Y. (2015):** Role of adipocytokines in the induction of experimental non alcoholic fatty liver disease. Am J Med Med Sci ; 5:175–180.
- 51- **Elbadr, M.M. and El Badre, HM. (2020):** Hepatoprotective and antiobesity effects of mirabegron, a novel β 3-adrenoceptor agonist, on carbon tetrachloride-induced hepatotoxicity in obese rats. J Curr Med Res Pract ;5:254-61.
- 52- **Poekes, L.; Gillard, J.; Farrell, G.C. et al., (2019):** Activation of brown adipose tissue enhances the efficacy of caloric restriction for treatment of nonalcoholic steatohepatitis. Lab Invest.; 99, 4–16.
- 53- **Finlin, B.S. Memetimin, H.; Zhu, B. et al., (2020):** The β 3-adrenergic receptor agonist mirabegron improves glucose homeostasis in obese humans . JCI.; 130(5) :2147-2726.
- 54- **Calmasini. F.; De Oliveira, M. G.; Alexandre, E.C. and Silva, F.H. (2018):** Long-term treatment with the beta-3 adrenoceptor agonist, mirabegron ameliorates detrusor overactivity and restores

cyclic adenosine monophosphate (cAMP) levels in obese mice. *Neurourology and Urodynamics* 36(6).

- 55- **Wang, H.; Liu, L.; Lin, J.Z. et al., (2016):** Browning of white adipose tissue with roscovitine induces a distinct population of UCP1+ adipocytes. *Cell Metab.*;24:835–47.
- 56- **Poekes, L.; Legry, V.; Schakman, O. et al., (2017):** Defective adaptive thermogenesis contributes to metabolic syndrome and liver steatosis in obese mice. *Clin Sci.*;131:285–96.
- 57- **Roberts-Toler, C.; O'Neill, B.T.; Cypess, A.M. (2015):** Diet-induced obesity causes insulin resistance in mouse brown adipose tissue. *Brief Cutting Edge Report*; 23(9).
- 58- **Clooney, S.L.; Welly, R.J.; Shay, D. et al., (2019):** β 3 adrenergic receptor activation rescues metabolic dysfunction in female estrogen receptor alpha-null mice. *Front. Physiol.*; 10, 9.
- 59- **O'Mara, A.; Johnson, J.W.; Linderman, J.D. et al., (2020):** Chronic mirabegron treatment increases human brown fat, HDL cholesterol, and insulin sensitivity. *J Clin Invest.* ;130(5):2209–2219.
- 60- **Berbee, J.F.; Boon, M.R.; Khedoe, P.P. et al., (2015):** Brown fat activation reduces hypercholesterolaemia and protects from atherosclerosis development. *Nat Commun.*;6:6356.
- 61- **Cypess, A.M.; Weiner, L.S.; Roberts-Toler, C. et al., (2015):** Activation of human brown adipose tissue by a β 3-adrenergic receptor agonist. *Cell metabolism*, 21(1), 33–38.
- 62- **Sessa, F.; Messina, G.; Russo, R. et al. (2020):** Consequences on aging process and human wellness of generation of nitrogen and oxygen species during strenuous exercise. *Aging Male*; 23(1):14-22.
- 63- **Achari, A.E. and Jain, S.K. (2017):** Adiponectin, a therapeutic target for obesity, diabetes, and endothelial dysfunction. *Int. J. Mol. Sci.* ; 18(6):26-44.
- 64- **Polito, R.; Nigro, E.; Elce, A. et al. (2019):** Adiponectin expression is modulated by long-term physical activity in adult patients affected by cystic fibrosis. *Med. Inflamm.*
- 65- **Julian, V.; Thivel, D.; Costes, F. et al. (2018):** Eccentric training improves body composition by inducing mechanical and metabolic adaptations: a promising approach for overweight and obese individuals. *Front. Physiol.* ;9:10-13.

- 66- **Polito, R.; Monda, V.; Nigro, E. et al., (2020):** The Important Role of Adiponectin and Orexin-A, Two Key Proteins Improving Healthy Status: Focus on Physical Activity. *Frontiers in physiology*, 11, 356.
- 67- **Jain, M.R.; Giri, S.R.; Bhoi, B. et al., (2018):** Dual PPAR α/γ agonist saroglitazar improves liver histopathology and biochemistry in experimental NASH models. *Liver International*. 2018;38:1084–1094.
- 68- **Pai, R.K. (2019):** NAFLD Histology: a Critical Review and Comparison of Scoring Systems. *Curr Hepatology Rep* ;18, 473–481.
- 69- **Wang, M.; Weng, X.; Chen, H. et al., (2020):** Resveratrol inhibits TNF- α -induced inflammation to protect against renal ischemia/reperfusion injury in diabetic rats . *Acta Cir. Bras.*;35 (20).
- 70- **Kersten, S. (2014):** Integrated physiology and systems biology of PPARalpha. *Mol Metab*; 3(4): 354-371.